

# Ultralydsscanning - Hofte

Marius Fredriksen

arkadens fysioterapi

---

---

---

---

---

---

---

---

## Standard-projektioner

### Anterior projektion

- Caput femoris
- Ledspalte
- Labrum
- Recessus anterolaterale

### Iliopsoas

- Muskler: psoas maj. sene/muskel, iliacus
- Bursa iliopectinea

### Trochanter-regionen

- Muskler: glut.max., glut.med., glut.min., TFL
- Bursa trochanterica

Ultralydsscanning af hofte - Marius Fredriksen

arkadens fysioterapi

---

---

---

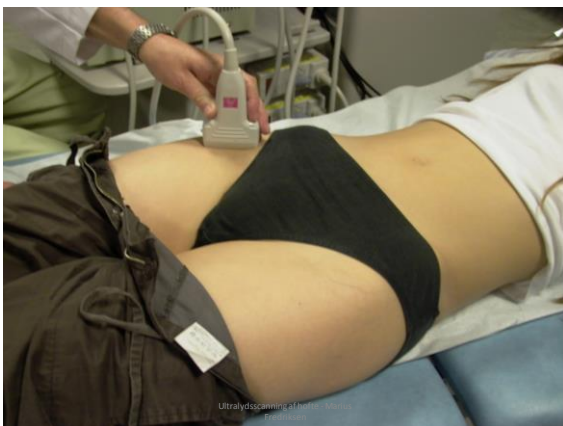---

---

---

---

---



Ultralydsscanning af hofte - Marius Fredriksen

---

---

---

---

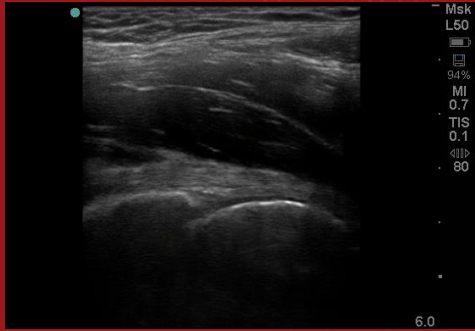
---

---

---

---

### Anterior projektion – Caput femoris



Ultralydsscanning af hofte - Marius Fredriksen

arkodens fysioterapi

---

---

---

---

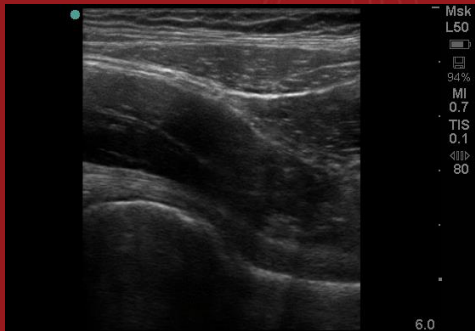
---

---

---

---

### Anterior projektion – Caput femoris



Ultralydsscanning af hofte - Marius Fredriksen

arkodens fysioterapi

---

---

---

---

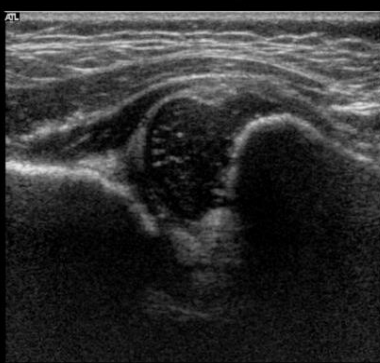---

---

---

---

Map 3  
170dB/C 5  
Persist Off  
2D Opt:FSCT  
Fr Rate:Surv  
SonoCT®



S I N

arkodens fysioterapi

---

---

---

---

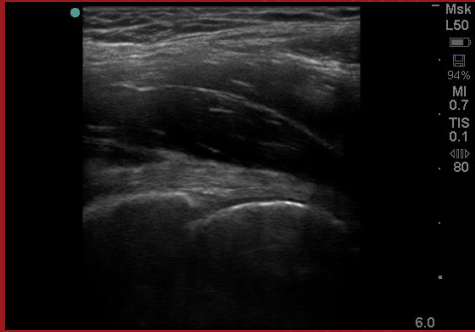---

---

---

---

### Anterior projektion – Ledspalte



Ultralydsscanning af hofte - Marius Fredriksen

arkadens fysioterapi

---

---

---

---

---

---

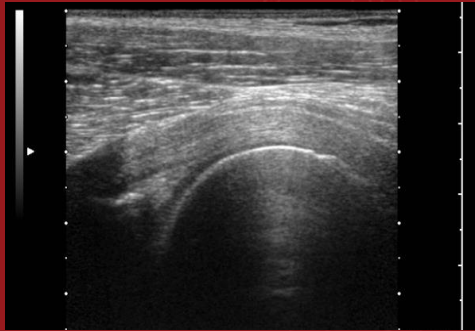
---

---

---

---

### Anterior projektion – Ledspalte



Ultralydsscanning af hofte - Marius Fredriksen

arkadens fysioterapi

---

---

---

---

---

---

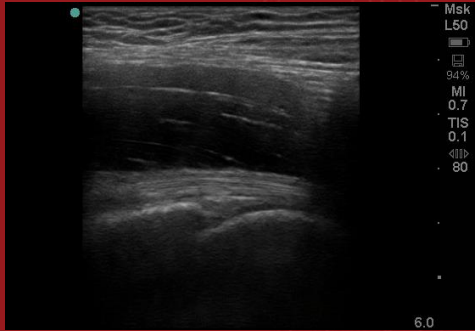
---

---

---

---

### Anterior projektion – Labrum



Ultralydsscanning af hofte - Marius Fredriksen

arkadens fysioterapi

---

---

---

---

---

---

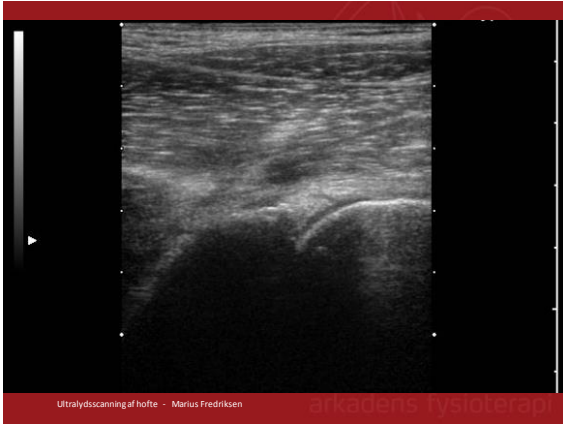---

---

---

---





---

---

---

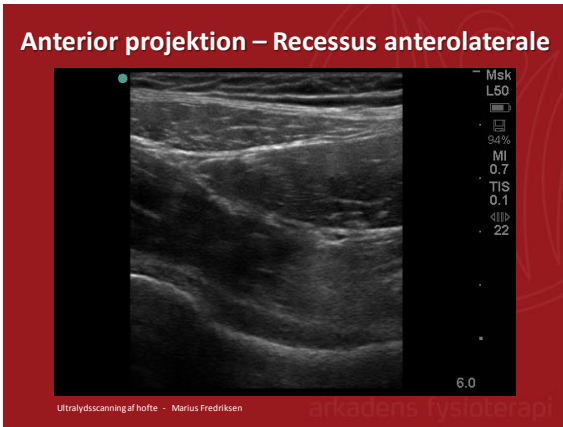
---

---

---

---

---



---

---

---

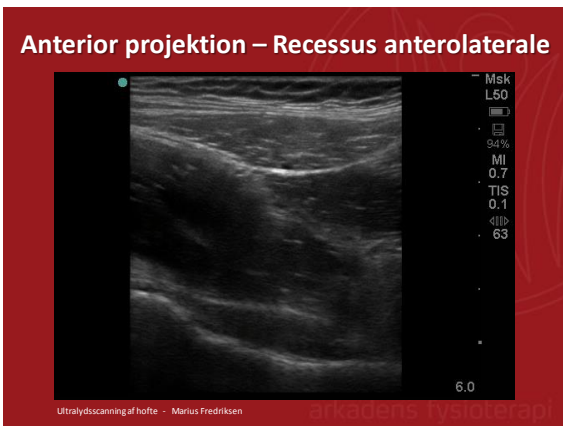
---

---

---

---

---



---

---

---

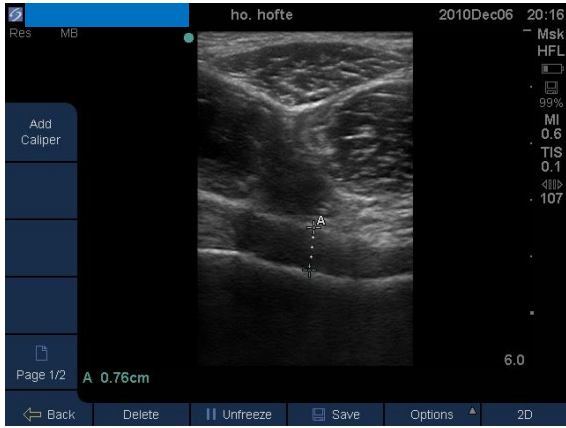
---

---

---

---

---



---

---

---

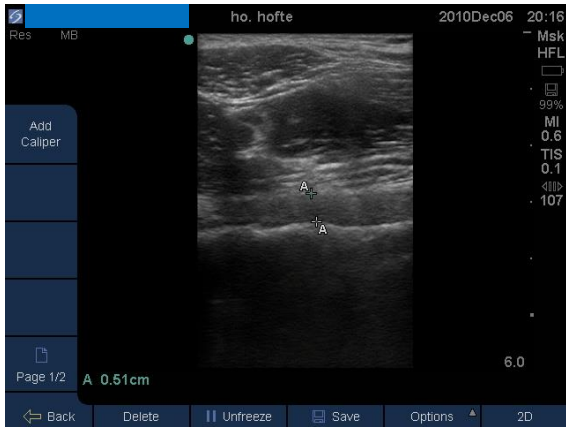
---

---

---

---

---



---

---

---

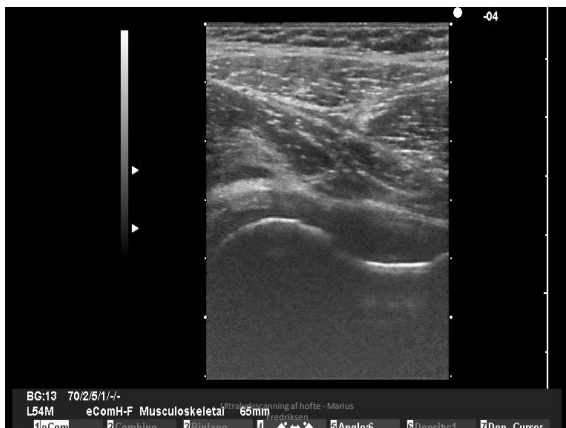
---

---

---

---

---



---

---

---

---

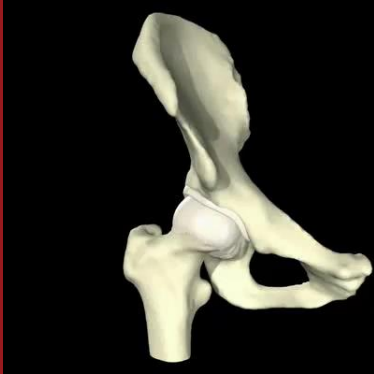---

---

---

---

FAI – CAM



terapi

---

---

---

---

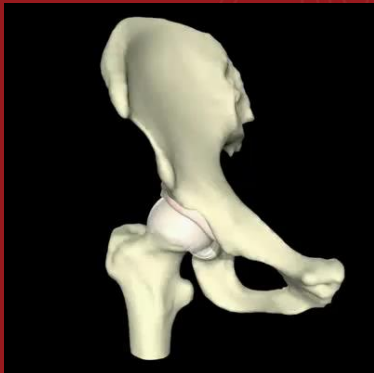---

---

---

---

FAI – PINCER



terapi

---

---

---

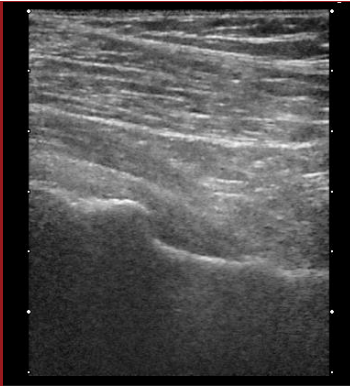
---

---

---

---

---



Ultralydsscanning af hoft - Marius Fredriksen

arkadens fysioterapi

---

---

---

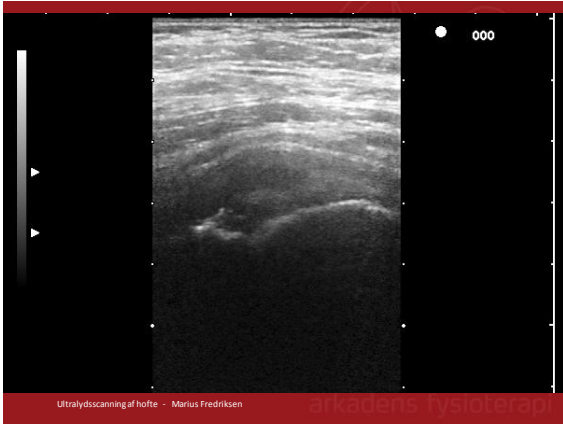---

---

---

---

---



---

---

---

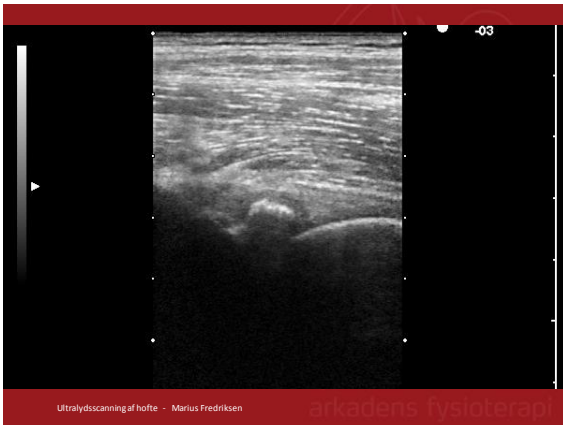---

---

---

---

---



---

---

---

---

---

---

---

---

## Standard-projektioner

Iliopsoas

- Muskler: psoas maj. sene/muskel, iliacus
- Bursa iliopectinea

Ultrasound scanning of the hip - Marius Fredriksen arkadens fysioterapi

---

---

---

---

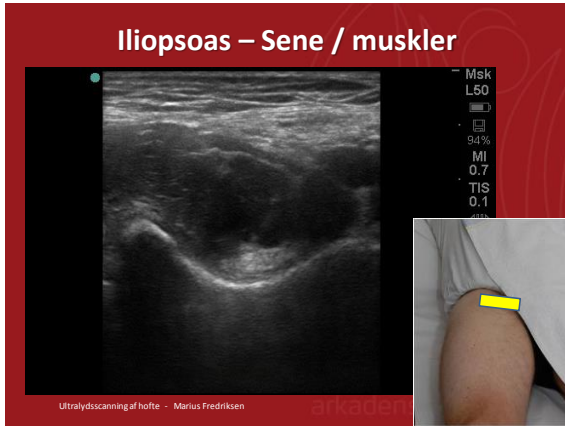
---

---

---

---





---

---

---

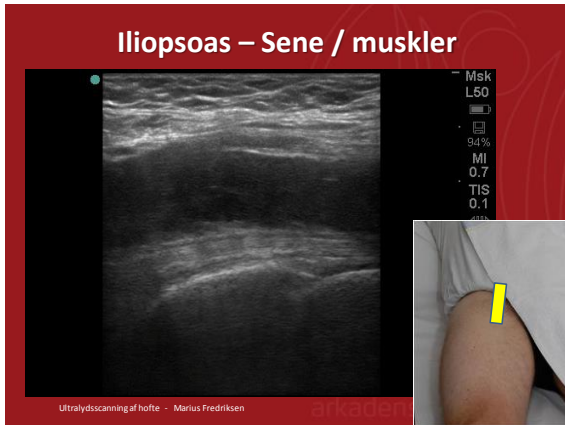
---

---

---

---

---



---

---

---

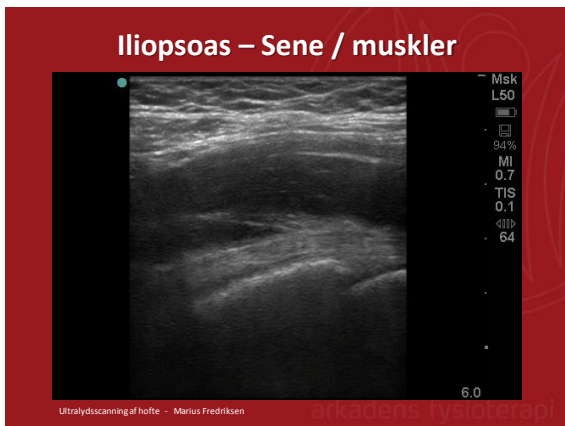
---

---

---

---

---



---

---

---

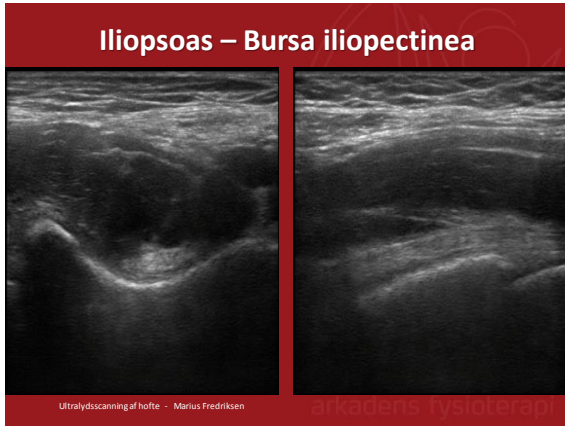
---

---

---

---

---



---

---

---

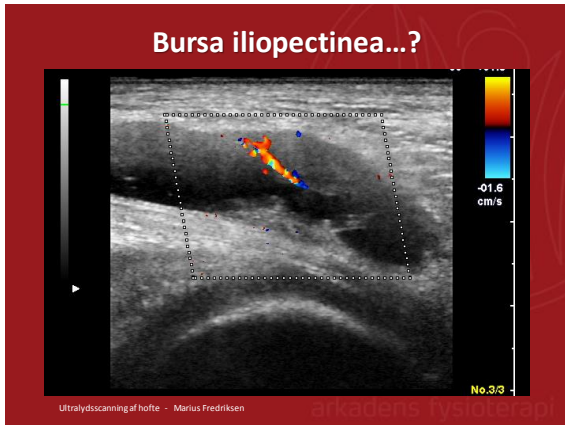
---

---

---

---

---



---

---

---

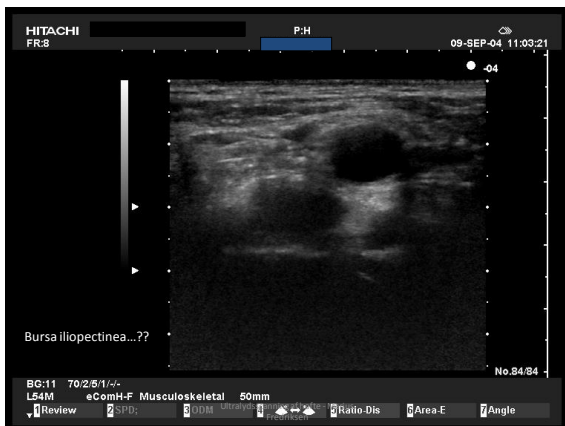
---

---

---

---

---



---

---

---

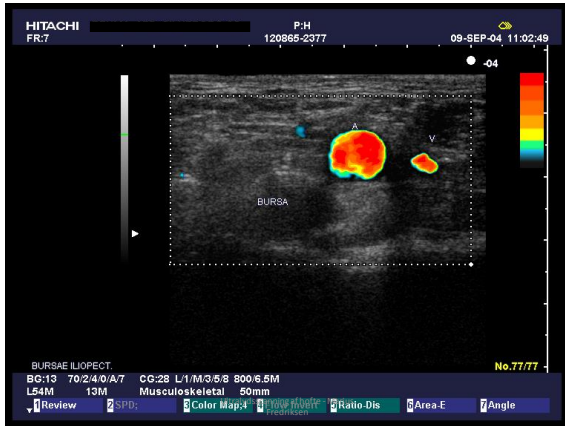
---

---

---

---

---



---

---

---

---

---

---

---

---

## Standard-projektioner

### Trochanter-regionen

- Muskler: glut.max., glut.med., glut.min., TFL
- Bursa trochanterica

Ultralydsscanning af hofte - Marius Fredriksen

arkadens fysioterapi

---

---

---

---

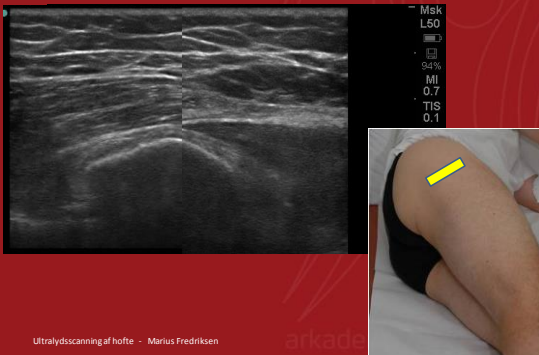
---

---

---

---

## Trochanter – Muskler



Ultralydsscanning af hofte - Marius Fredriksen

arkade

---

---

---

---

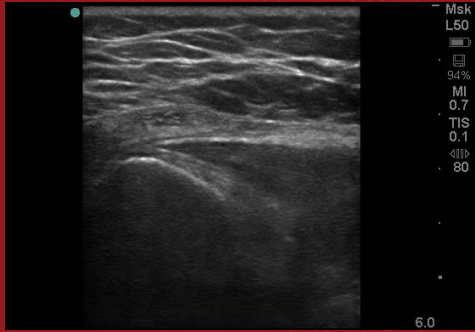---

---

---

---

### Trochanter – Muskler



Ultralydsscanning af hofte - Marius Fredriksen

arkadens fysioterapi

---

---

---

---

---

---

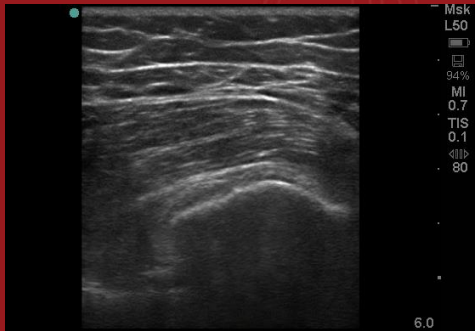---

---

---

---

### Trochanter – Muskler



Ultralydsscanning af hofte - Marius Fredriksen

arkadens fysioterapi

---

---

---

---

---

---

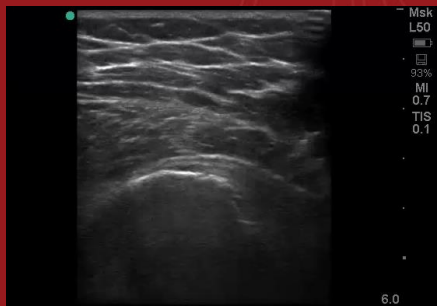---

---

---

---

### Trochanter – Bursa trochanterica



Ultralydsscanning af hofte - Marius Fredriksen

arkadens fysioterapi

---

---

---

---

---

---

---

---

---

---

# DEMO

Ultralydsscanning af hofte - Marius Fredriksen  
arkadens fysioterapi

---

---

---

---

---

---

---

---

## DEMO – Standard-projektioner

### Anterior projektion

- Caput femoris
- Ledspalte
- Labrum
- Recessus anterolaterale

### Iliopsoas

- Muskler: psoas maj. sene/muskel, iliacus
- Bursa iliopectinea

### Trochanter-regionen

- Muskler: glut.max., glut.med., glut.min., TFL
- Bursa trochanterica

Ultralydsscanning af hofte - Marius Fredriksen  
arkadens fysioterapi

---

---

---

---

---

---

---

---