

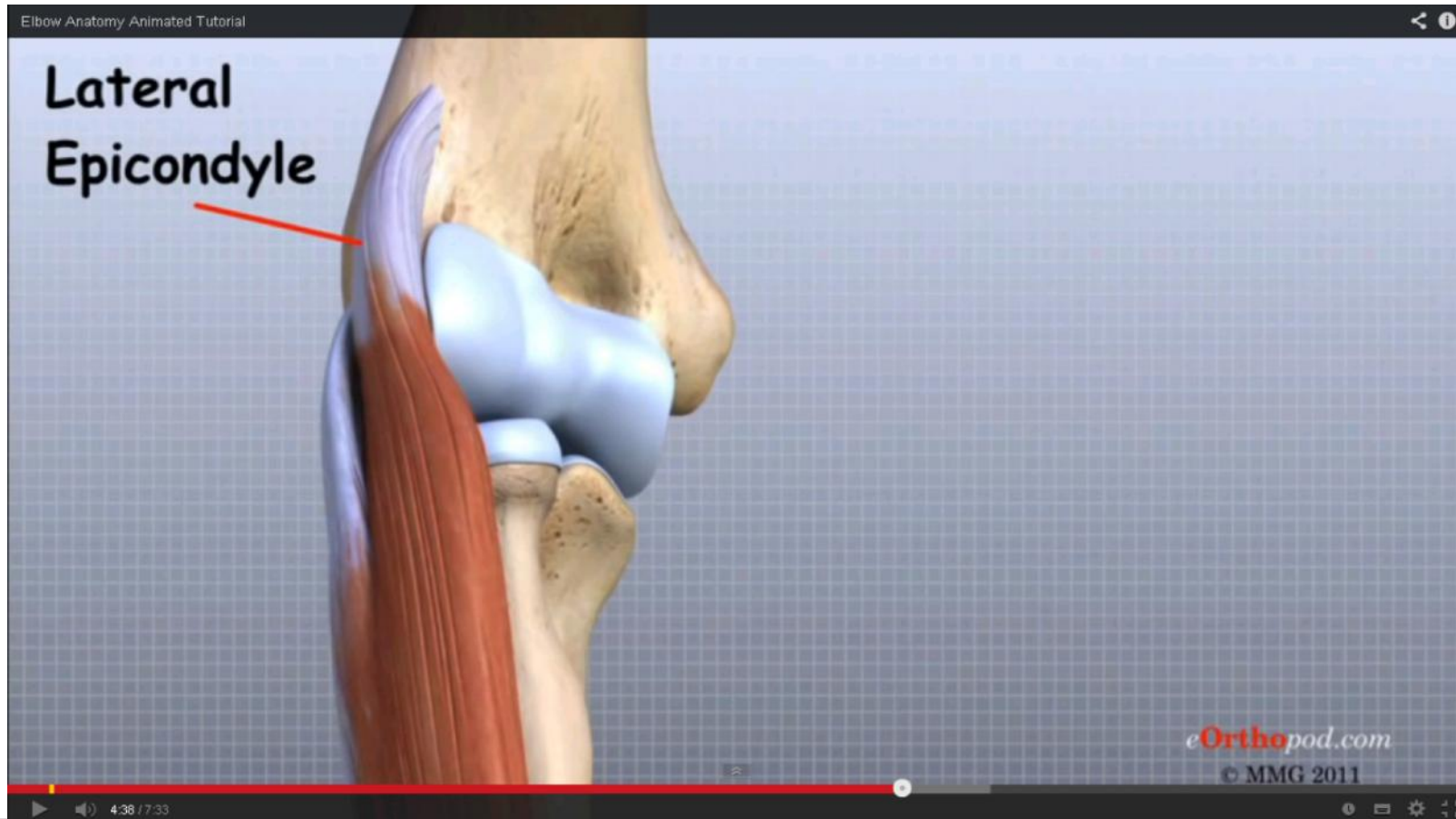
Ultralydsskanning Albue/Hånd

Niels Honoré

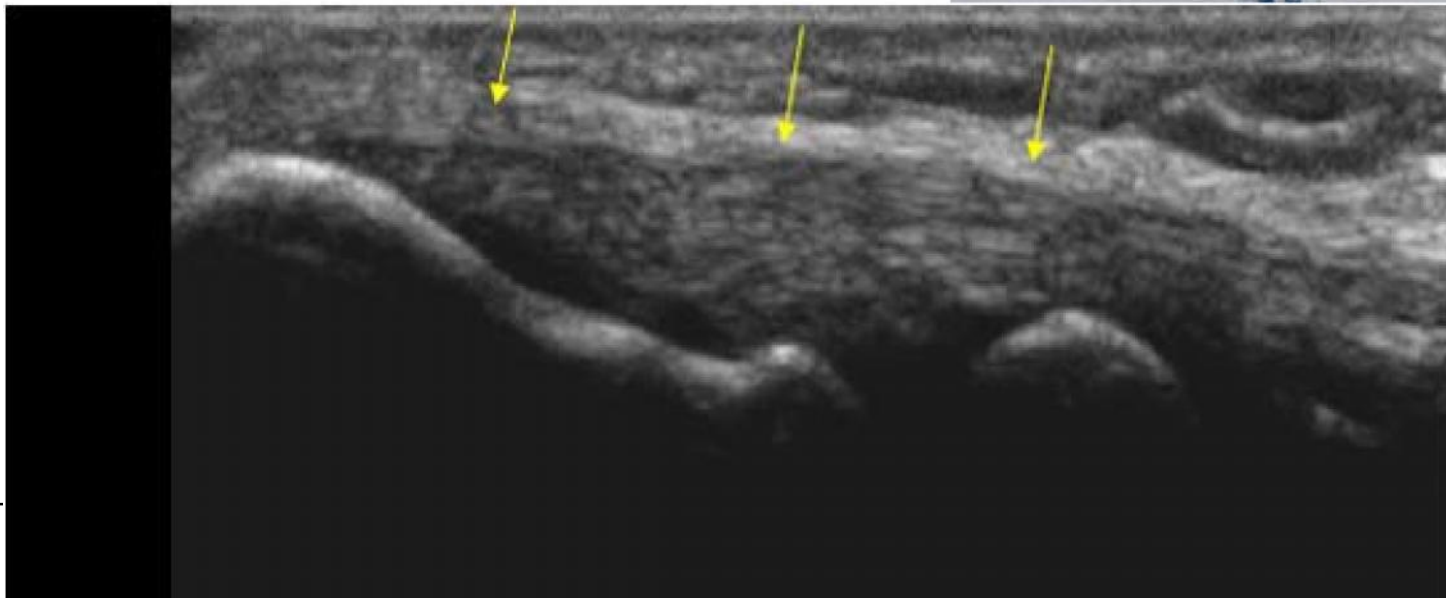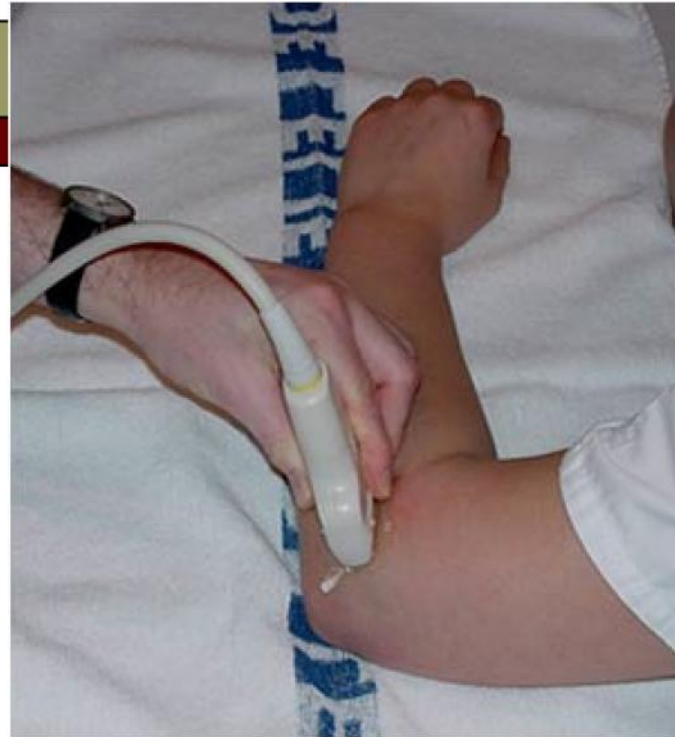Pjojektioner

- ① Epicondyl lat
- ② Epicondyl med
- ③ Caput radii
- ④ Triceps longitudinelt/transverselt
- ⑤ Flexor/extensorsener
- ⑥ N. medianus

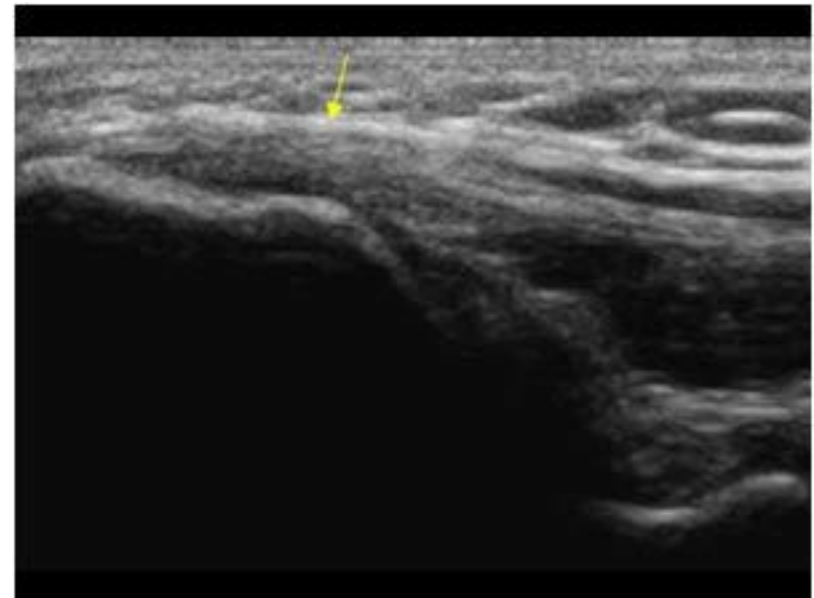
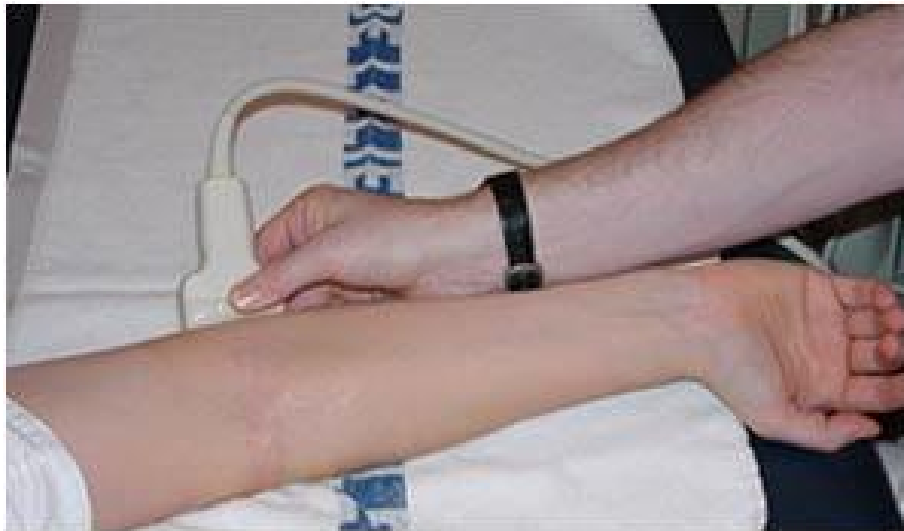Albue leddet



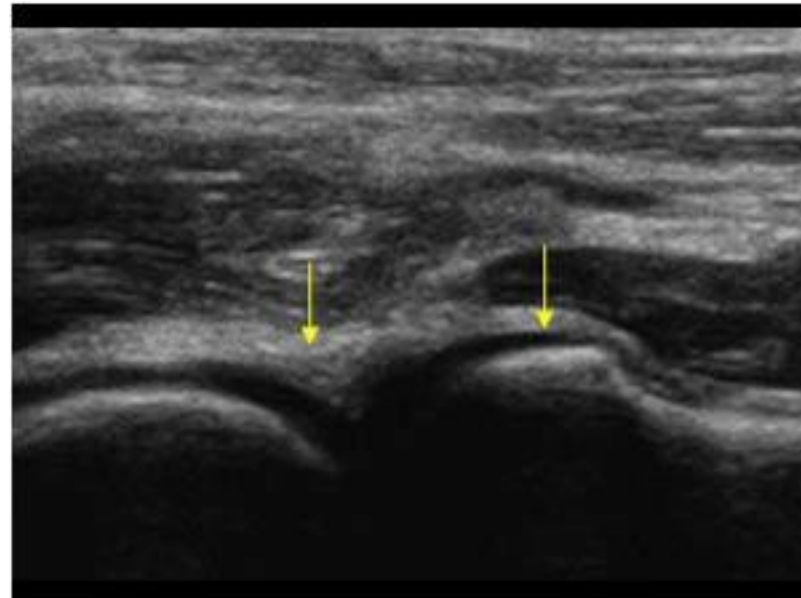
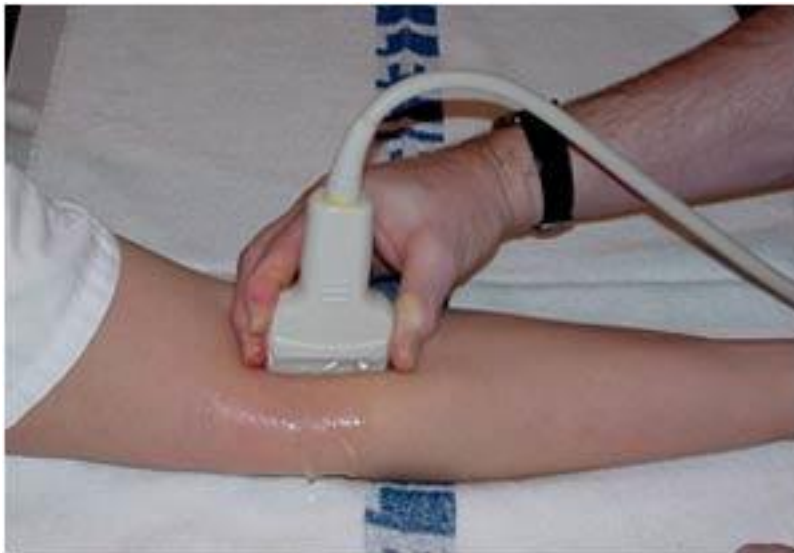Common extensor tendon insertion longitudinal



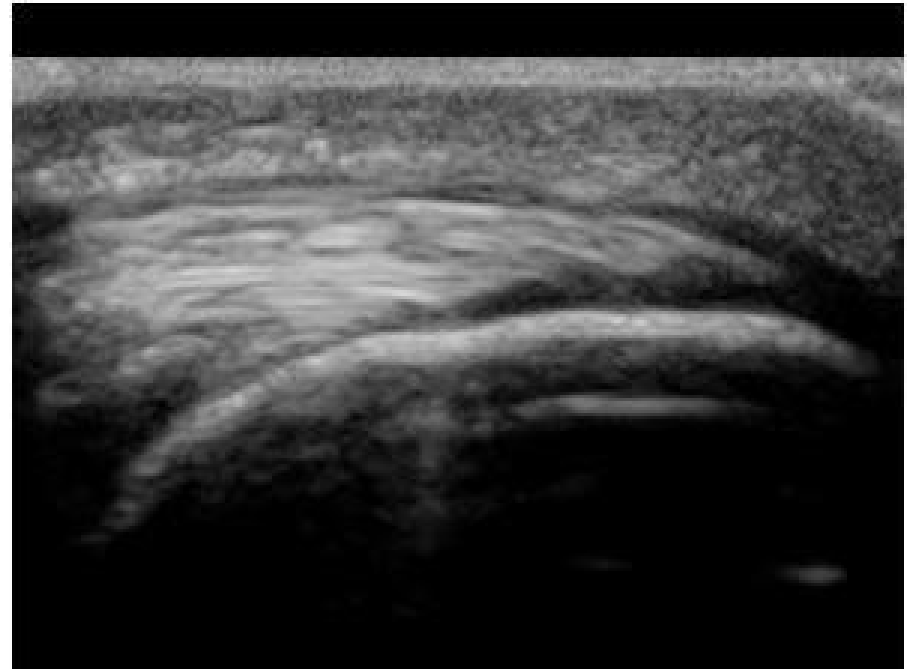
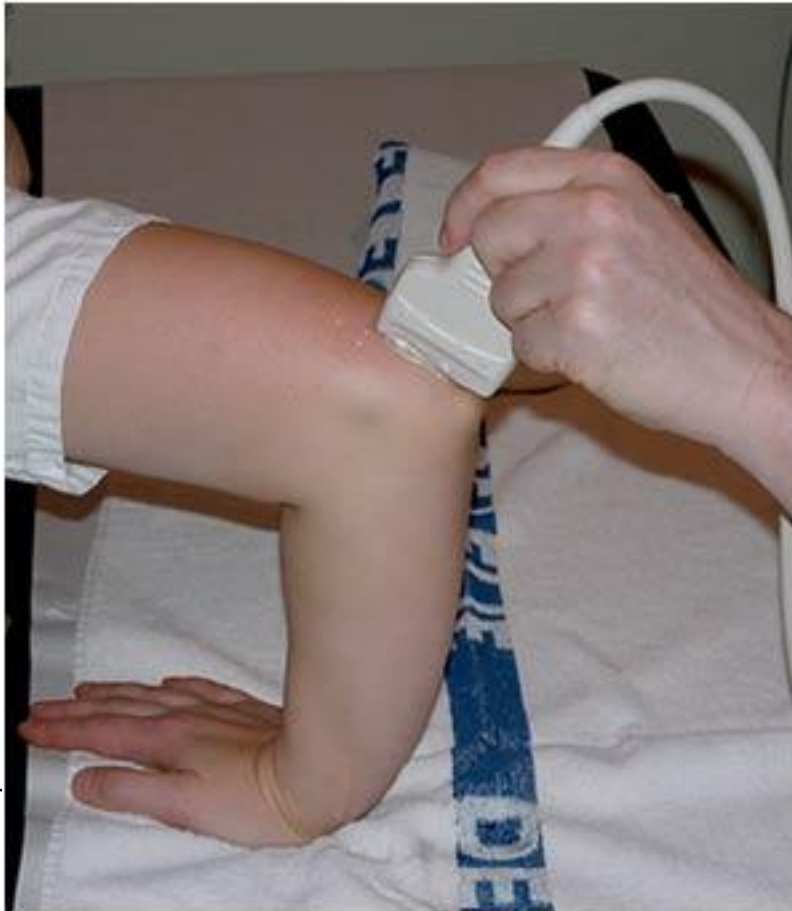Common flexor tendon insertion longitudinal



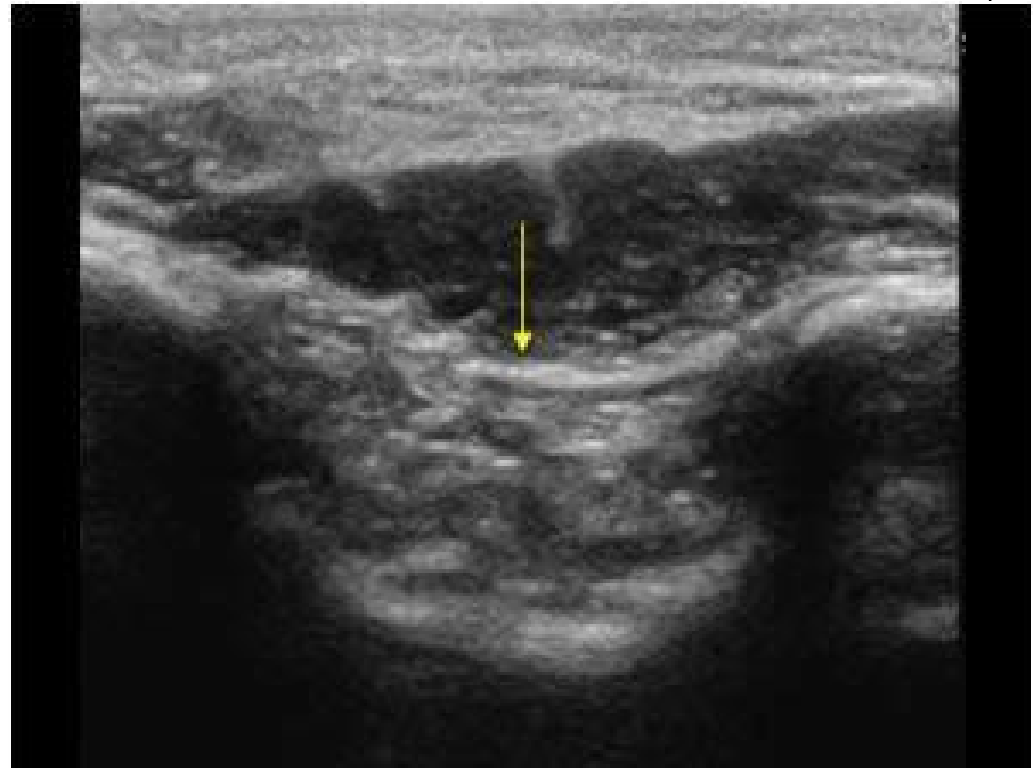
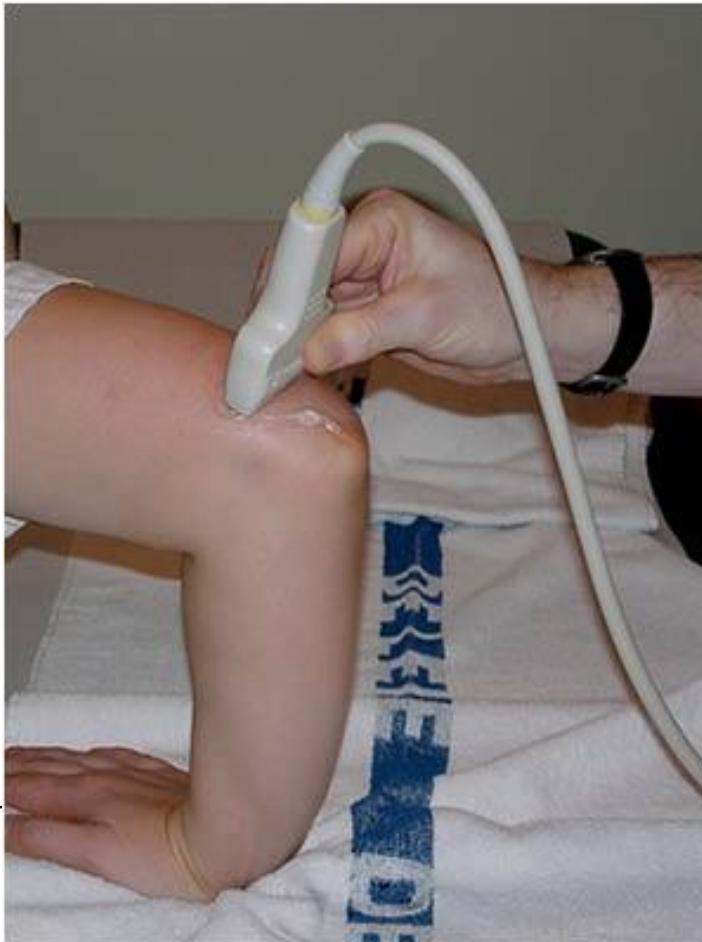Radial head capsule longitudinal



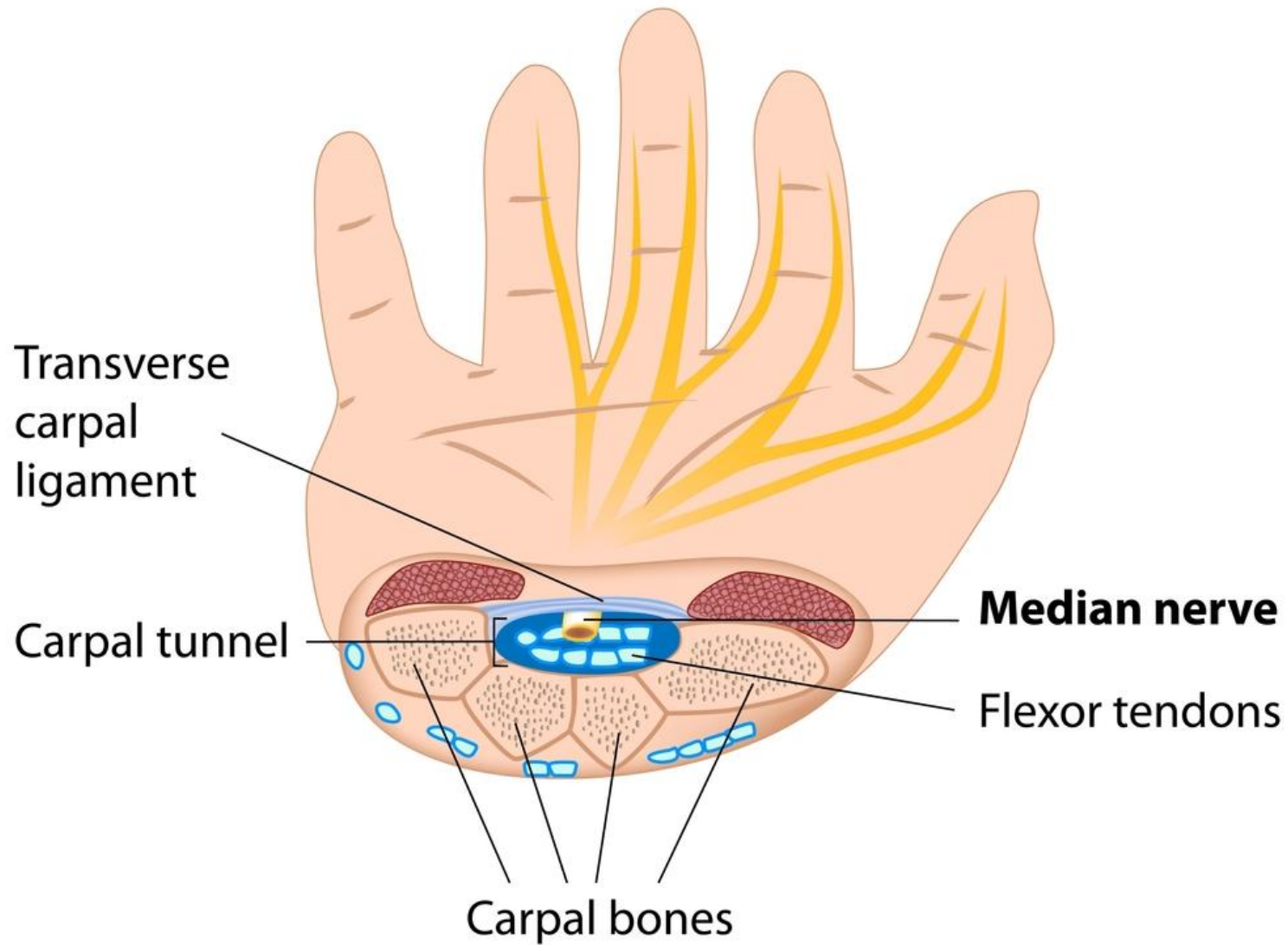
Triceps tendon insertion longitudinal



Olecranon fossa filled with fat transverse



The Carpal Tunnel



Carpal Tunnel Syndrome

